Elaine M. Caoili, MD
Melvyn Korobkin, MD
Isaac R. Francis, MD
Richard H. Cohan, MD
Joel F. Platt, MD
N. Reed Dunnick, MD
Kartik I. Raghupathi, BS

Adrenal Masses: Characterization with Combined Unenhanced and Delayed Enhanced CT[1]

Index terms:
Adrenal gland, CT, 86.12111, 86.12113, 86.12114
Adrenal gland, neoplasms, 86.317, 86.33
Computed tomography (CT), contrast enhancement, 86.12113, 86.12114

Published online before print 10.1148/radiol.2223010766
Radiology 2002; 222:629–633

[1] From the Department of Radiology (E.M.C., M.K., I.R.F., R.H.C., J.F.P., N.R.D.) and Consortium for Health Outcomes, Innovation, and Cost Effectiveness Studies (K.I.R.), University of Michigan Medical Center, 1500 E Medical Center Dr, Ann Arbor, MI 48109-9723. From the 2000 RSNA scientific assembly. Received April 9, 2001; revision requested April 30; final revision received October 3; accepted October 9. **Address correspondence to** E.M.C. (e-mail: *caoili@umich.edu*).

Author contributions:
Guarantors of integrity of entire study, E.M.C., M.K.; study concepts, E.M.C., M.K., I.R.F., R.H.C., J.F.P., N.R.D.; study design, E.M.C., M.K.; literature research, E.M.C., M.K.; clinical studies, E.M.C., M.K.; data acquisition, E.M.C.; data analysis/interpretation, K.I.R., E.M.C., M.K.; statistical analysis, K.I.R., E.M.C.; manuscript preparation, E.M.C., M.K.; manuscript definition of intellectual content, all authors; manuscript editing, E.M.C., M.K.; manuscript revision/review, E.M.C., K.I.R.; manuscript final version approval, E.M.C., M.K., I.R.F., R.H.C., J.F.P., N.R.D.

PURPOSE: To assess the accuracy of a dedicated adrenal computed tomographic (CT) protocol.

MATERIALS AND METHODS: One hundred sixty-six adrenal masses were evaluated with a protocol consisting of unenhanced CT, and, for those with attenuation values greater than 10 HU, contrast material–enhanced and delayed enhanced CT. Attenuation values and enhancement washout calculations were obtained. An adenoma was diagnosed if a mass had an attenuation value of 10 HU or less at unenhanced CT or a percentage enhancement washout value of 60% or higher.

RESULTS: The final diagnosis was adenoma in 127 masses and nonadenoma in 39. Masses measuring more than 10 HU on unenhanced CT scans were confirmed at biopsy ($n = 28$) or were examined for stability or change in size at follow-up CT performed at a minimum interval of 6 months ($n = 33$). Thirty-six (92%) of 39 nonadenomas and 124 (98%) of 127 adenomas were correctly characterized. The sensitivity and specificity of this protocol were 98% and 92%, respectively. This protocol correctly characterized 160 (96%) of 166 masses.

CONCLUSION: With a combination of unenhanced and delayed enhanced CT, nearly all adrenal masses can be correctly categorized as adenomas or nonadenomas.

The discovery of an unsuspected adrenal mass is common, occurring in up to 5% of patients undergoing abdominal computed tomography (CT) (1). Even in patients with a known extraadrenal malignancy, most adrenal masses are adenomas (1). Various threshold attenuation values have been reported to distinguish adrenal adenomas from nonadenomas at unenhanced and delayed contrast material–enhanced CT imaging (2–6). The variability in the reported attenuation values at CT may reflect different imaging techniques used with different CT scanners. Boland et al (2) analyzed reports of a number of studies that evaluated attenuation values at unenhanced CT and concluded that a threshold of 10 HU or less corresponded to a sensitivity of 71% and a specificity of 98% in the diagnosis of adrenal adenoma. Enhancement washout curves have also been successfully used to distinguish adrenal adenomas from adrenal nonadenomas (7–10) at delayed enhanced CT imaging.

The purpose of this study was to assess the accuracy of a dedicated adrenal CT protocol combining both attenuation values at unenhanced CT and enhancement washout calculations in differentiating adenomas from nonadenomas.

MATERIALS AND METHODS

Our study was approved by our institutional review board, and informed consent was waived. One hundred eighty consecutive adrenal masses were evaluated with a dedicated adrenal CT imaging protocol. The examinations were performed during a 36-month period from February 1997 to February 2000. Two masses with grossly visible fatty components (less than or equal to −30 HU) were presumed to be myelolipomas and were

excluded from the study. Two masses were evaluated twice over several years; therefore, only the findings from the initial examinations were included. Ten additional masses were excluded because of inadequate follow-up. A diagnosis was established in the final study group of 166 masses when histologic proof was obtained at surgery or percutaneous biopsy ($n = 46$), when stability or change in size of the mass was observed at a subsequent CT examination with a minimum of 6 months follow-up ($n = 55$), or when an attenuation value of 10 HU or less was identified on unenhanced CT scans ($n = 65$). Of the final study group, 112 masses were included in a previous study on specific enhancement characteristics of lipid-poor adrenal adenomas (10).

The dedicated adrenal CT protocol consisted of initial densitometry of the mass on unenhanced CT scans. If the mass had an attenuation of 10 HU or less, it was assumed to be benign and probably a lipid-rich adenoma, and no further imaging was performed and no further evaluation was recommended. All patients with adrenal masses that had attenuation values greater than 10 HU at unenhanced imaging underwent enhanced CT imaging 60 seconds after intravenous administration of contrast material and then underwent delayed enhanced CT imaging at 15 minutes. All three phases were performed with the same scanner. Enhancement washout percentages were calculated for these masses. To diagnose an adrenal mass as an adenoma, we used the previously reported thresholds of 60% or higher for enhancement washout and 40% or higher for relative enhancement washout (7,10).

The CT scans were obtained with either a nonhelical unit (HiSpeed Advantage; GE Medical Systems, Milwaukee, Wis) or a helical unit (HiLite Advantage or LightSpeed CT/i; GE Medical Systems). Parameters for the unenhanced and delayed enhanced examinations with both helical units included 3- or 5-mm collimation, 1:1 pitch, 120 kVp, and 200–280 mA. Enhanced imaging was performed with collimation of 5, 7, or 10 mm and a 1:1 pitch. Imaging parameters for the CT/i unit were similar for all three phases and consisted of the following: 5-mm collimation, 1:1 pitch, 120 kVp, and 200–280 mA. Enhanced scans were obtained after intravenous injection of 150 mL of diatrizoate sodium 50 (Hypaque; Nycomed, New York, NY) or iohexol 300 (Omnipaque; Nycomed). Intravenous contrast material was administered with a power injector at a rate of 2.0–3.0 mL/sec.

CT attenuation values were measured by using a circular region of interest on images of the adrenal lesion in question. The region of interest covered at least one-half of the mass, excluding cystic, calcified, or necrotic regions. The edges of the adrenal lesion were avoided to prevent partial volume averaging. At least two measurements were obtained for each mass at each imaging phase. The same radiologist recorded the mean attenuation values and then calculated the enhancement washout percentages with the following equation: percentage of enhancement washout = ([attenuation value at enhanced CT − attenuation value at delayed enhanced CT]/[attenuation value at enhanced CT − attenuation value at unenhanced CT]) × 100. The relative percentage of enhancement washout was also calculated for all adrenal masses with the following equation: relative percentage of enhancement washout = ([attenuation value at enhanced CT − attenuation value at delayed enhanced CT]/attenuation value at enhanced CT) × 100. The maximal diameters and the right or left side locations of the adrenal masses were also recorded by the same radiologist.

The data contained a type of repeated measures: 15 patients who had bilateral masses measured at a given CT examination. A repeated-measures analysis of variance was undertaken to examine the significance of the differences between the three groups of masses (lipid rich, lipid poor, and nonadenoma) in terms of mean mass size, mean attenuation value at unenhanced CT, mean attenuation value at enhanced CT, mean attenuation value at delayed enhanced CT, mean percentage of enhancement washout, and mean relative percentage of enhancement washout. Repeated-measures analysis of variance with the patient (rather than the mass) as the unit of observation allowed us to account for the statistical possibility that the bilateral masses in a single patient were somehow correlated and to ensure that the differences between the three groups of masses that were found to be statistically significant were not influenced in any way by variation within a single patient. A P value less than .05 was considered to indicate a statistically significant difference. The threshold values of 60% or higher for absolute percentage enhancement washout and 40% or higher for relative percentage enhancement washout used in the diagnosis of adenoma were established in prior investigations (7,10).

RESULTS

The final clinical diagnosis was adrenal adenoma for 127 masses and nonadenoma for 39 masses. On the basis of attenuation values at unenhanced CT, 105 of the adenomas were characterized as lipid rich and 22 adenomas were characterized as lipid poor. The diagnosis of lipid-rich adenoma was established in 105 cases based solely on attenuation values of 10 HU or less at unenhanced CT. Further confirmation of this diagnosis in 39 of these 105 cases was based on the stability of the mass at subsequent CT examinations performed at a minimum interval of 6 months ($n = 21$) or on the results of histopathologic examinations ($n = 18$). The final diagnosis of lipid-poor adenoma (ie, adenomas with an attenuation value at unenhanced CT > 10 HU) was confirmed at histopathologic examination ($n = 10$) or with stability of the mass on follow-up CT images ($n = 12$). The diagnosis of nonadenoma in 39 cases was confirmed at pathologic examination ($n = 18$) or with growth or shrinkage of the mass on follow-up CT images ($n = 21$).

The patient population with adrenal adenomas consisted of 70 women and 46 men with a mean age of 52 years (range, 30–83 years). In 11 of these patients, there were bilateral adrenal masses. The patient population with nonadenomas consisted of 12 women and 23 men with a mean age of 60 years (range, 36–76 years). Four patients had bilateral adrenal masses. The nonadenomas included 34 metastases, two pheochromocytomas, one hematoma, one adrenal cortical carcinoma, and one angiosarcoma. The primary malignancies in the 30 patients who had adrenal metastases were the following: lung cancer ($n = 15$), esophageal cancer ($n = 3$), renal cancer ($n = 4$), melanoma ($n = 2$), tongue cancer ($n = 1$), rectal cancer ($n = 1$), lymphoma ($n = 1$), prostate cancer ($n = 1$), breast cancer ($n = 1$), and leiomyosarcoma ($n = 1$).

There was no significant difference in the maximal diameter between the lipid-rich and the lipid-poor adenomas ($P = .68$). The average maximal diameter of the lipid-rich adenomas was 2.2 cm (range, 1.0–6.0 cm), whereas that of the lipid-poor adenomas was 2.4 cm (range, 1.0–4.2 cm). Nonadenomas were larger (mean size, 4.0 cm; range, 1.3–12.0 cm) than both lipid-rich and lipid-poor adenomas. Lipid-rich adenomas were more often found in the left ($n = 69$) than in the right ($n = 36$) adrenal gland. Lipid-

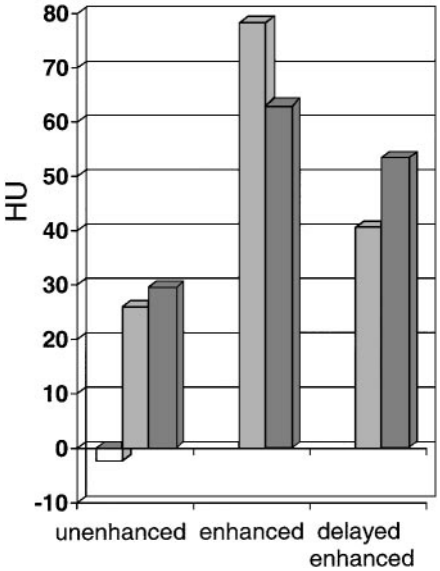

Figure 1. Bar graph of the mean attenuation values (HU) at unenhanced, enhanced, and delayed enhanced CT of all adrenal masses shows that lipid-poor adenomas could not be distinguished from nonadenomas based on attenuation values at unenhanced CT. White bar = lipid-rich adenomas, light gray bar = lipid-poor adenomas, dark gray bar = nonadenomas.

poor adenomas were also more often present in the left (n = 12) than in the right (n = 10) gland. Nonadenomas were found in the left adrenal gland in 18 cases and in the right adrenal gland in 21 cases.

The mean attenuation values of lipid-rich adenomas, lipid-poor adenomas, and nonadenomas on unenhanced, enhanced, and delayed enhanced CT scans are shown in Figure 1. The mean unenhanced value of the lipid-poor adenomas was significantly higher than that of the lipid-rich adenomas (25.9 HU vs −2.3 HU, $P < .001$) but was not significantly different from that of the nonadenomas (29.5 HU, $P = .13$). The mean attenuation value of the lipid-poor adenomas at enhanced CT was significantly higher than that of the nonadenomas (78.3 HU vs 63.2 HU, $P = .012$). The mean attenuation value of the lipid-poor adenomas at delayed enhanced CT was significantly lower than that of the nonadenomas (40.6 HU vs 53.3 HU, $P = .021$). Although the means of the attenuation values at enhanced CT and the attenuation values at delayed enhanced CT for lipid-poor adenomas and nonadenomas were significantly different, there was too much overlap among the individual values of the two groups to permit differentiation between them for any individual mass.

The mean percentage enhancement washout value of the lipid-poor adenomas was significantly higher than that of the nonadenomas (70.7% vs 22.5%, $P <$ .001). The percentage enhancement washout values for the lipid-poor adenomas and the nonadenomas are shown in Figure 2. In addition, the relative percentage enhancement washout value of the lipid-poor adenomas was also significantly higher than that of the nonadenomas (46.8% vs 12.9%, $P < .001$).

The use of a threshold of 60% in the differentiation of lipid-poor adenomas from nonadenomas (10) resulted in a sensitivity of 86% (19 of 22 masses) and a specificity of 92% (36 of 39 masses) (Fig 2). There were three lipid-poor adenomas that did not meet the 60% threshold. The percentage enhancement washout measurements for these masses were 51%, 53%, and 58%. The use of a relative percentage enhancement washout threshold value of 40% in the differentiation of the lipid-poor adenomas (10) resulted in a sensitivity of 82% (18 of 22 masses) and a specificity of 92% (36 of 39 masses). The percentage enhancement washout measurements for the four lipid-poor adenomas that did not meet the 40% relative percentage enhancement threshold were 31%, 36%, 38%, and 39%. Two of the lipid-poor adenomas did not meet either threshold criteria.

Three nonadenomas had percentage enhancement washout measurements above the 60% threshold (Fig 2). These included a pheochromocytoma, which had a washout measurement of 68%, a well-differentiated adrenal cortical carcinoma, which had a washout measurement of 81%, and a renal cell carcinoma metastasis, which had a washout measurement of 66%. The relative percentage enhancement washout measurements for these masses were 47%, 53%, and 33%, respectively.

Assuming that all of the adrenal masses of 10 HU or less were correctly characterized as lipid-rich adenomas, our dedicated adrenal protocol correctly characterized 160 (96%) of 166 adrenal masses. The sensitivity and specificity of this protocol for characterizing an adrenal mass as an adenoma versus a nonadenoma were 98% (124 of 127 masses) and 92% (36 of 39 masses), respectively. If we exclude the nonadenomas that were not metastases, the sensitivity and specificity of this protocol for characterizing an adrenal mass as an adenoma versus a metastasis were 98% (124 of 127 masses) and 97% (33 of 34 masses), respectively.

DISCUSSION

There are two independent properties of adrenal adenomas that can be exploited in characterizing them at CT. First, most adenomas contain large amounts of intracellular lipid, resulting in lower attenuation values at unenhanced CT than nonadenomas. Second, all adenomas, including those without substantial lipid content, tend to have a more rapid loss of attenuation value soon after enhancement with intravenous contrast material. The purpose of our investigation was to evaluate a protocol that takes advantage of both properties in an attempt to improve the assessment of these adrenal masses. By limiting contrast enhancement to those adrenal masses without substantial lipid content, the risk, cost, and time required for delayed enhancement studies are minimized. Prior investigations have focused primarily on one characteristic or another. To the best of our knowledge, evaluation of the accuracy of a protocol combining these two properties has not been reported.

In this protocol, the threshold value of 10 HU or less on unenhanced CT images characterized 105 lipid-rich adenomas of 127 adenomas. Use of the percentage enhancement washout threshold of 60% allowed us to correctly diagnose 19 of 22 lipid-poor adenomas. Combining attenuation values at unenhanced CT and a percentage enhancement washout threshold of 60% for adrenal lipid-poor adenomas (ie, those measuring > 10 HU on unenhanced CT scans) into one protocol yields a sensitivity of 98% (124 of 127 masses) in the diagnosis of adenoma. The specificity of this protocol in distinguishing an adenoma from all nonadenomas is 92% (36 of 39 cases), but the specificity increases to 97% (34 of 35 masses) if adenomas are compared only with metastases. Using this protocol, we correctly distinguished adenomas from nonadenomas in 160 (96%) of 166 cases and from metastases in 157 (98%) of 161 cases.

In patients with a known extraadrenal primary neoplasm, differentiation of an adenoma from a metastasis is the principal reason an adrenal mass is characterized. Nonadenomas such as pheochromocytomas and primary adrenal malignancies are rare, and the former can usually be diagnosed by virtue of their clinical and biochemical features. If one assesses only the adenomas and metastases in our series, the differentiation of which is the more common diagnostic dilemma (compared with differentiating

an adenoma from a primary adrenal neoplasm), the specificity increases from 92% to 97%. Only one renal cell carcinoma metastasis did not have a percentage enhancement washout value of 60% or less.

The ability of unenhanced CT densitometry to help diagnose adrenal adenomas has been extensively studied. A number of these investigations established that adenomas consistently have lower attenuation values than nonadenomas (2–4). Korobkin et al (11) demonstrated that the amount of intratumoral lipid content of resected adrenal adenomas directly correlated with a lower attenuation value at unenhanced CT. Boland et al (2) critically analyzed the reported attenuation values of adenomas and nonadenomas in 10 published series of adrenal masses and concluded that a threshold of 10 HU on unenhanced CT images corresponded to a sensitivity of 71% and a specificity of 98% in the diagnosis of adrenal adenoma (2). With such a high specificity, it is very likely that a mass that is 10 HU or less on unenhanced CT images is an adenoma. In addition, several researchers in studies of delayed enhanced CT of adrenal masses have used an attenuation value of 10 HU or less at unenhanced CT as the sole proof that a mass was an adenoma (7,10). Although we did not recommend additional proof of the diagnosis of a lipid-rich adenoma in this study, 39 of the 105 presumed lipid-rich adenomas were confirmed as such at either histopathologic examination or CT follow-up. However, considering all prior evidence, we concluded that all masses of 10 HU or less on unenhanced CT images in this study were lipid-rich adenomas and included this assumption in the calculations of the accuracy of the dedicated CT protocol.

Investigators have also evaluated the use of attenuation values at delayed enhanced CT and calculations of percentage enhancement washout in the differentiation of adrenal adenomas from nonadenomas. Korobkin et al (7) determined that adenomas demonstrate a greater percentage of enhancement washout compared with nonadenomas. Szolar and Kammerhuber (8) and Pena et al (9) reported similar results. Most of the adenomas in these reports were of the more common lipid-rich type. More recently, however, it has been shown that early delayed enhancement washout calculations of lipid-poor adenomas are nearly identical to those of the lipid-rich variety and therefore can also be used to differentiate lipid-poor adenomas from nonadenomas (10).

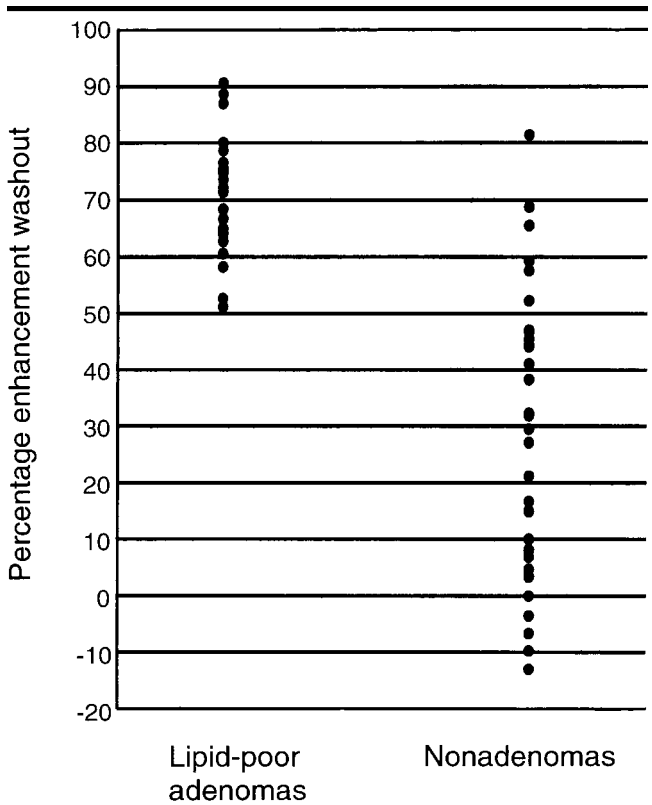

Figure 2. Scatterplot shows the percentage enhancement washout values for lipid-poor adenomas and nonadenomas. Nearly all lipid-poor adenomas could be diagnosed with the 60% threshold.

The results of our study confirm those of prior studies and demonstrate that the mean attenuation values at unenhanced CT of lipid-poor adrenal adenomas and those of nonadenomas are nearly identical. Although the two groups have significantly different mean attenuation values at both enhanced and delayed enhanced CT, the considerable overlap between the two groups is too large to permit sufficiently accurate differentiation between them for any individual case. The distribution of the enhancement washout calculations for the two groups, however, was significantly different to allow accurate differentiation of individual cases. With use of the previously reported threshold of 60% for percentage of enhancement washout on CT scans obtained 15 minutes after administration of contrast material (7,10), our sensitivity was 86% (19 of 22 cases), with a specificity of 92% (36 of 39 cases). With the threshold of 60%, we correctly diagnosed 19 of 22 lipid-poor adenomas. The remaining three lipid-poor adenomas had percentage enhancement washout values ranging from 51% to 58%. With the 60% threshold, we correctly diagnosed 36 of 39 nonadenomas. The three nonadenomas that had percentage enhancement washout values greater than 60% included an atypical adrenal cortical carcinoma, a pheochromocytoma, and a renal cell carcinoma metastasis.

There are few reports on the CT attenuation washout curves of nonadenomas other than metastases. One recent study demonstrated that five of six pheochromocytomas had washout curves similar to those of metastases (8), but one had a washout curve similar to that of adenomas, as the pheochromocytoma in our study did. Six adrenal cortical carcinomas were included in the group of nonadenomas in the study by Szolar and Kammerhuber (8). These carcinomas, however, were not distinguished from the other nonadenomas, and it is unknown how close their washout values were to the threshold. In addition, our single example of adrenal cortical carcinoma was a 3-cm, highly differentiated neoplasm whose only pathologic feature of malignancy was the presence of frequent mitotic figures. This may represent an atypical example whose enhancement washout is similar to that of an adenoma.

The relative enhancement washout value is an approximation of the true enhancement washout value; it relates the decrease in attenuation value on delayed enhanced images to the initial enhanced value, instead of to the difference between the enhanced and the unenhanced values. Initially described as an alternative calculation to be used when an unenhanced scan was not obtained, it is identical to the true enhancement washout only for lipid-rich adenomas with attenuation of 0 HU at unenhanced CT. On the basis of the results of prior studies (7,10), we used a threshold relative enhancement washout value of 40% in the differentiation of lipid-poor adenomas from nonadenomas in this study. At this threshold, the sensitivity was 82% (18 of 22 cases) and the specificity was 92% (36 of 39 cases)—lower than the sensitivity of 96% and specificity of 100% for a combined group of lipid-poor and mainly lipid-rich adenomas (7). It is not surprising that the relative enhancement washout value is less helpful in distinguishing lipid-poor adenomas than it is in distinguishing lipid-rich adenomas. If the higher attenuation value at unenhanced CT is not included in the denominator of the equation for true enhancement washout, the relative enhancement washout value will be closer to the value for nonadenomas. Use of the true enhancement washout value should be more accurate than use of the relative enhancement washout value in the differentiation of lipid-poor adenomas from nonadenomas.

There are several limitations to our study. First, many of the patients with lipid-rich adenomas did not undergo follow-up. The diagnosis of lipid-rich adenomas was based on the attenuation value at unenhanced CT. However, use of the criterion of attenuation values at unenhanced CT has been validated in several previous investigations (2,4,7), as well as in our own results, in which 39 lipid-rich adenomas were confirmed. Many clinicians at our hospital have accepted this criterion and are subsequently not requesting additional follow-up. Second, although it is common to use a 6-month follow-up to help determine benignity, slow-growing malignancies can occur and may appear as stable masses at subsequent examinations. This would affect our accuracy calculations, but, to our knowledge, there have been no false diagnoses other than those we have already described. In fact, adrenal adenomas have occasionally shown growth. In a study by Barzon and colleagues (12), adrenal adenomas demonstrated an 8% cumulative risk of enlargement after 1 year. Although none of the enlarged adrenal adenomas developed malignancy, any adrenal masses in our investigation that showed increased growth within a 6-month interval would have been considered suspicious, and further follow-up would have been recommended. Third, partial volume averaging errors could have been made in the measurements of our smaller masses, particularly during the enhanced imaging procedure when the collimation varied from 5- to 10-mm sections. This may have falsely lowered the recorded attenuation values. Fourth, several adrenal masses measuring more than 10 HU on unenhanced CT images were not included in this analysis. Some patients with known extraadrenal malignancy and an adrenal mass did not undergo unenhanced or delayed enhanced imaging; their adrenal masses were presumed to be metastases and were treated clinically as such. Thus, our study population is somewhat selective and does not reflect the true prevalence of adrenal disease.

In summary, lipid-rich adenomas can be characterized with an attenuation value of 10 HU or less at unenhanced CT. Lipid-poor adenomas can be differentiated from nonadenomas at delayed enhanced CT examinations with percentage enhancement washout calculations. Combining these techniques into a single protocol enables nearly all adrenal masses to be diagnosed with a high sensitivity and specificity.

References

1. Korobkin M, Francis IR, Kloos RT, Dunnick NR. The incidental adrenal mass. Radiol Clin North Am 1996; 34:1037–1054.
2. Boland GW, Lee MJ, Gazelle GS, Halpern EF, McNicholas MMJ, Mueller PR. Characterization of adrenal masses using unenhanced CT: an analysis of the CT literature. AJR Am J Roentgenol 1998; 171: 201–204.
3. Lee MJ, Hahn PF, Papanicolau N, et al. Benign and malignant adrenal masses: CT distinction with attenuation coefficients, size, and observer analysis. Radiology 1991; 179:415–418.
4. Korobkin M, Brodeur FJ, Yutzy GG, et al. Differentiation of adrenal adenomas from nonadenomas using CT attenuation values. AJR Am J Roentgenol 1996; 166:531–536.
5. Boland GW, Hahn PF, Pena C, Mueller PR. Adrenal masses: characterization with delayed contrast-enhanced CT. Radiology 1997; 202:693–696.
6. Cieszanowski A, Rozniatowski B, Pacho RA, Zaniewicz K, Dabrowska E. Characterization of adrenal masses with unenhanced CT and delayed contrast-enhanced CT (abstr). Radiology 1999; 213(P):178.
7. Korobkin M, Brodeur FJ, Francis IR, Quint LE, Dunnick NR, Londy F. CT time-attenuation washout curves of adrenal adenomas and nonadenomas. AJR Am J Roentgenol 1998; 170:747–752.
8. Szolar DH, Kammerhuber FH. Adrenal adenomas and nonadenomas: assessment of washout at delayed contrast-enhanced CT. Radiology 1998; 207:369–375.
9. Pena CS, Boland GW, Hahn PF, Lee MJ, Mueller PR. Characterization of indeterminate (lipid-poor) adrenal masses: use of washout characteristics at contrast-enhanced CT. Radiology 2000; 217:798–802.
10. Caoili EM, Korobkin M, Francis IR, Cohan RH, Dunnick NR. Delayed enhanced CT of lipid-poor adrenal adenomas. AJR Am J Roentgenol 2000; 175:1411–1415.
11. Korobkin M, Giordano TJ, Brodeur FJ, et al. Adrenal adenomas: relationship between histologic lipid and CT and MR findings. Radiology 1996; 200:743–747.
12. Barzon L, Scaroni C, Sonino N, Fallo F, Paoletta A, Boscaro M. Risk factors and long-term follow-up of adrenal incidentalomas. J Clin Endocrinol Metab 1999; 84: 520–526.