

LIVER DOPPLER

Patient Name _____

Date _____ Ordering _____ Tech _____

DOB _____

Indication _____

MRN _____

	Patent	Thrombus	Flow Direction	Velocity
Portal V				
Main	Yes No	Partial Complete	Antegrade/ Retrograde	_____ cm/s
Left	Yes No	Partial Complete	Antegrade/ Retrograde	_____ cm/s
Right	Yes No	Partial Complete	Antegrade/ Retrograde	_____ cm/s
Hepatic A				
Main	Yes No			_____ cm/s
Left	Yes No			
Right	Yes No			
Hepatic Vs				
Left	Yes No			
Mid	Yes No			
Right	Yes No			
IVC	Yes No	Partial Complete		
Splenic V	Yes No	Partial Complete	Antegrade/ Retrograde	

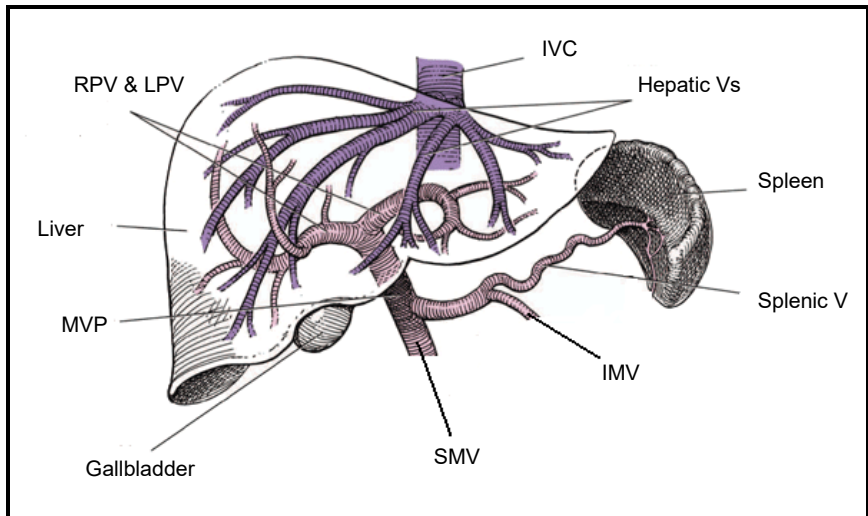
AP Diameter of MPV _____ cm

Ascites Yes No

Collaterals Yes No

Spleen _____ cm

COMMENTS



Portal Veins (Main, Left and Right) - normal blood flow is ANTEGRADE FLOW.
 Splenic Vein - normal blood flow is ANTEGRADE FLOW.
 ANTEGRADE (Hepatopetal) Flow is toward the liver.
 RETROGRADE (Hepatofugal) Flow is away from the liver (wrong direction).